

CASE REPORT

# Prehospital conversion of paroxysmal supraventricular tachycardia using the modified Valsalva maneuver: A case report

Padarath Gangaram<sup>1,\*</sup>, Yugan Pillay<sup>1</sup>, Bernard Christopher Pillay<sup>1</sup>, Guillaume Alinier<sup>1,2,3</sup>

Address for Correspondence:

**Padarath Gangaram**

<sup>1</sup>Ambulance Service, Hamad Medical Corporation, Doha, Qatar

<sup>2</sup>School of Health & Social Work, University of Hertfordshire, Hatfield, UK

<sup>3</sup>Weill Cornell Medicine-Qatar, Doha, Qatar  
Email: pgangaram@hamad.qa

<http://dx.doi.org/10.5339/qmj.2020.33>

Submitted: 01 April 2020

Accepted: 06 June 2020

© 2020 Gangaram, Pillay, Alinier, licensee HBKU Press. This is an open access article distributed under the terms of the Creative Commons Attribution license CC BY 4.0, which permits unrestricted use, distribution and reproduction in any medium, provided the original work is properly cited.

Cite this article as: Gangaram P, Pillay Y, Pillay B C, Alinier G. Prehospital conversion of paroxysmal supraventricular tachycardia using the modified Valsalva maneuver: A case report, Qatar Medical Journal 2020;33 <http://dx.doi.org/10.5339/qmj.2020.33>

كيساينس  
QSCIENCE  
دار جامعة حمد بن خليفة للنشر  
HAMAD BIN KHALIFA UNIVERSITY PRESS

## ABSTRACT

The modified Valsalva maneuver (MVM) has never before been performed in the prehospital setting by the Hamad Medical Corporation Ambulance Service (HMCAS) clinicians in the State of Qatar. Currently, their clinical practice guidelines (CPG) prescribe the vagal maneuver (VM) using a 10 cc syringe as first-line therapy for patients presenting with symptomatic paroxysmal supraventricular tachycardia (pSVT). The effectiveness of the MVM in terminating pSVT compared to the traditional VM is well documented, although prehospital studies in this area are lacking. In this case, a generally healthy, 47-year-old male migrant worker presented with new-onset symptomatic pSVT, which was successfully terminated by a MVM after initial failed attempts of the traditional VM. The MVM is a postural technique performed by initially placing the patient in a semirecumbent position. The patient is then encouraged to blow into a manometer to achieve a 40 mmHg intrathoracic pressure for 15 seconds. Once the 40 mmHg intrathoracic pressure is achieved, the patient is repositioned supine, and their legs are raised passively to 45 degrees for 15 seconds. The patient is then returned to the semirecumbent position for 45 seconds before cardiac rhythm reassessment. The MVM has shown to have an increased termination rate of pSVT with no documented serious adverse events. The MVM can be performed in a time-effective manner and is cost effective as intravenous (IV) cannulation is not required. The prevention of adenosine-associated transient asystole is prevented. It is recommended that ambulance services consider the inclusion of the MVM in their CPGs for the treatment of new-onset pSVT.

**Keywords** vagal maneuver, modified Valsalva maneuver, paroxysmal supraventricular tachycardia

## INTRODUCTION

In the general population, the estimated incidence of supraventricular tachycardias (SVT) is 35 per 1,000,000 person-years with a prevalence of 2.25 per 1000 persons.<sup>1</sup> The Hamad Medical Corporation Ambulance Service (HMCAS) in Qatar treats approximately 220 patients presenting with SVT annually.

Paroxysmal supraventricular tachycardia (pSVT) is generally characterized by a regular tachycardia that starts suddenly, terminates abruptly, and classically presents with a narrow QRS complex,<sup>2</sup> which is typically caused by reentry conducting pathways.<sup>3</sup> The pSVT phenomenon may be categorized into three groups: atrioventricular nodal reentrant tachycardia (AVNRT), atrioventricular reciprocating tachycardia (AVRT), and atrial tachycardia (AT).<sup>2</sup> This classification excludes other forms of SVT including atrial fibrillation and atrial flutter.<sup>2</sup> AVNRT is the most common type of SVT (approximately 50–60%) and is essentially caused by nodal reentry pathways that can be fast or slow,<sup>4</sup> typically resulting from antegrade conduction through the slow atrioventricular nodal (AVN) path and retrograde conduction through its fast paths. AVRT caused by reentry pathways occurs in approximately 30% of pSVT patients. The reentry pathways include antegrade transmission through the AVN (orthodromic) and retrograde transmission through the AVN (antidromic).<sup>4</sup> The least occurring AT (approximately 10%) is caused by automaticity or triggered activity, either focal, multifocal, or macro-reentry.<sup>4,5</sup>

In the emergency setting, the risks associated with pSVT can be extreme,<sup>6</sup> and require the immediate conversion to normal cardiac rhythm using the most appropriate technique. The risks associated with persistent pSVT may include hemodynamic collapse, cardiac tamponade, acute myocardial infarction, congestive heart failure, syncope, deep vein thrombosis, systemic embolism, and sudden death related to Wolff–Parkinson–White syndrome.<sup>2,4,5</sup>

Vagal maneuvers are the first-line of treatment for patients with pSVT.<sup>2,4,7</sup> However, other more aggressive treatment modalities for life-threatening pSVTs include pharmacological therapies and electrical shocks.<sup>8</sup> According to HMCAS CPG, patients pre-

senting with pSVTs are categorized into three groups: life-threatening, symptomatic, and asymptomatic.<sup>9</sup> A VM is performed initially on patients with symptomatic pSVT presentations. Patients in this category are coached by the attending paramedic and instructed to blow into a 10 cc syringe for 15 s in an attempt to move the plunger. Resistant pSVTs are managed with adenosine 6–18 milligrams (mg). Patients with immediately life-threatening pSVTs receive synchronized electrical cardioversion, and asymptomatic patients are transported to the hospital for further evaluation and care.

The VM is routinely used in the emergency setting for symptomatic pSVT.<sup>2,7</sup> However, its effectiveness in resolving pSVTs is only 5–20%.<sup>10</sup> Smith and Boyle<sup>11</sup> reported that the action of blowing into a 10 cc syringe and moving the plunger was sufficient to generate a 40 mm Hg intrathoracic pressure, enough to achieve optimum pressure for effective vagal tone.<sup>12</sup>

An English randomized controlled trial (RCT) that enrolled 433 participants was conducted over two years to determine whether the MVM was more effective than traditional VM methods in terminating pSVTs.<sup>10</sup> Five participants were excluded from the study, and 214 participants were allocated to each of the two groups. The traditional VM group achieved rhythm conversion in 37 (17%) patients while the MVM group achieved conversion in 93 (43%) patients (adjusted odds ratio 3.7 (95% CI 2.3–5.8;  $p < 0.0001$ )). No adverse events were reported. The English trial recommended the MVM as first-line treatment for patients presenting with symptomatic pSVT.

The MVM is more effective over other SVT terminating methods as it can be performed in a time-efficient manner. Also, the procedure is cost effective as intravenous cannulation is not required. It prevents adenosine-associated arrhythmias.<sup>7,13</sup> Certain ambulance services (e.g., Queensland Ambulance Service) have incorporated the MVM in their CPGs to mitigate against the associated risks.<sup>14</sup>

The researchers<sup>10</sup> recorded the MVM technique as follows (Figure 1):

Step 1: Place the patient in the semirecumbent position.

Step 2: Achieve a 40 mm Hg intrathoracic pressure for 15 seconds by asking the patient to blow into a manometer.

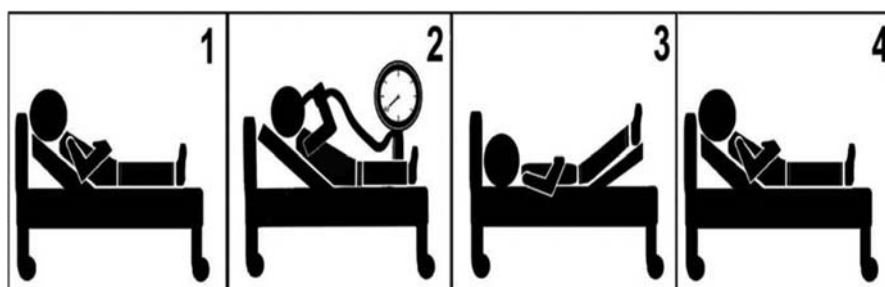

Figure 1. Modified Valsalva maneuver technique

Step 3: Once the 40 mm Hg intrathoracic pressure is achieved, then reposition the patient supine and passively raise the patient's legs to 45 degrees for 15 seconds.

Step 4: Return the patient to the semirecumbent position for 45 seconds before cardiac rhythm reassessment.

Walker and Cutting<sup>15</sup> also noted a significant improvement in pSVT conversion rates using the MVM from 5.3% to 31.7% in the absence of noteworthy adverse events. We report a healthy 47-year-old male migrant worker who presented with new-onset symptomatic pSVT that was successfully terminated using the MVM.

## CASE REPORT

This case report is part of routine practice and standard of care, including patient consent during care. No ethical boundaries were breached during care and reporting. The permission for publication of this case report was granted by the Medical Research Center (MRC-04-18-044) on the condition of patient anonymity.

A 47-year-old male patient requested emergency assistance with the chief complaint of chest pain and

palpitations. A team of Ambulance Paramedics (AP) and Critical Care Paramedics (CCP) were dispatched. The AP team arrived on the scene within eight minutes and found an alert and orientated patient complaining of nonradiating chest pain and palpitations that started abruptly at rest. The chest pain worsened with breathing and scored a 6/10 on a pain severity scale. The patient reported no previous medical history and that this was his first episode of chest pain. Socially, he was a nonsmoker and did not consume alcohol products. Caffeine products consumption and sleep deprivation were ruled out. The AP crew treated the patient for chest pain with oral acetylsalicylic acid and sublingual nitrates.<sup>9</sup> A 12-lead electrocardiogram (ECG) revealed a pSVT (Figure 2), with a heart rate of 194 beats per minute (highest recorded was 204 beats per minute) and normal blood pressure. No abnormalities were detected in his random blood sugar level, temperature, and lung fields with an oxygen saturation > 95% in ambient air.

The patient was placed in the semirecumbent position on the ambulance stretcher, and the VM using a 10 cc syringe was initiated by the AP crew, with no success. At HMCAS, the AP crew are not licensed to treat a VM-resistant pSVT either pharmacologically or with electrical shocks. A copy of the 12-lead ECG was

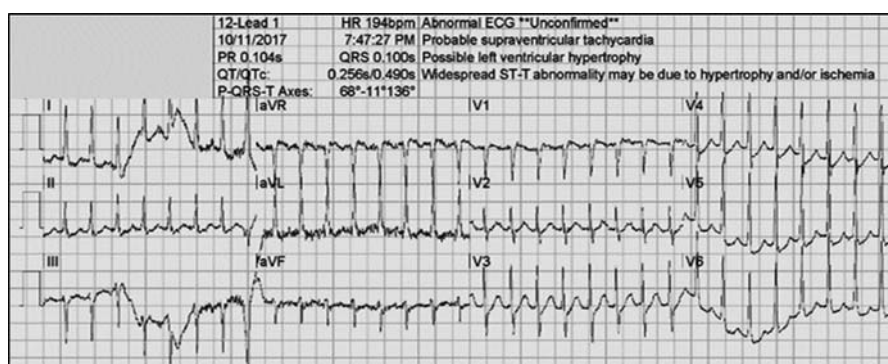


Figure 2. Electrocardiogram 1: pSVT

transmitted by telemetry to the Clinical Team Leader, who remotely advised the AP crew on a further treatment plan.

The CCP did rendez-vous with the AP crew, and after an initial assessment and confirmation of the pSVT, the CCP performed the MVM, as advocated by Appleboam et al.,<sup>10</sup> Sixty seconds later the pSVT converted to nonsustained bradycardia and then to sustained sinus rhythm with no ischemic changes (Figure 3). Post-conversion, the patient remained hemodynamically stable for hospital admission.

At follow-up, he showed that his ECG remained stable to hospital discharge 24 hours later. No abnormalities were noted in the patient's blood tests (full blood count, urea and electrolytes, and liver function tests). The patient was prescribed beta-blockers daily for review. At his two-month follow-up, the patient remained stable following cardiology review.

## DISCUSSION

A generally healthy 47-year-old male migrant worker presented with a pSVT for the first time, which was successfully converted by performing the MVM as described earlier. Subsequently, a rhythm change was noted from nonsustained bradycardia to sustained sinus rhythm. The rationale for performing the MVM was attributed to the traditional VM being unsuccessful.<sup>16</sup> Escalating the patient's treatment to pharmacological and electrical shock treatment modalities was not deemed appropriate at that time. These types of treatment have an increased risk profile as compared to the MVM.<sup>12,17,18</sup>

MVM can be rapidly performed by skilled practitioners. Minimal practical postural technique training will be required by practitioners to perform the MVM. Successful conversion of a pSVT using the MVM minimizes the need for IV cannulation to administer

adenosine and therefore reduces the cost burden on the patient and associated risks of transient asystole.<sup>19</sup> No additional equipment is required to perform the MVM.

In a case study, Morley-Smith et al.,<sup>20</sup> reported the successful conversion of a 7-year-old patient with an SVT using the MVM. The researchers described the MVM as being superior as compared to IV cannulation and drug therapy in children. Performing the MVM was less time-consuming and distressing to children, and more cost effective as compared to IV adenosine.<sup>20</sup>

The risks associated with prolonged episodes of pSVT can be detrimental to the patient's outcome.<sup>6</sup> The pSVT may have resolved 10 minutes earlier, minimizing any possible associated risks, if the AP crew had been trained and licensed to perform the MVM.<sup>21</sup>

The effectiveness of the MVM in terminating pSVT compared to the traditional VM is well documented,<sup>10,15,17,21,22</sup> although prehospital studies in this area are limited. Until recently, most ambulance services have not included the MVM in their CPGs.<sup>14</sup> The MVM technique identified by the REVERT trial is achievable in the prehospital environment in many ambulance services without additional logistical requirements and minimal training of first-responding AP.

In a recent study, Mohammad et al.,<sup>13</sup> achieved a 47.3% conversion rate of SVT by using the MVM in Iraq, which was higher than earlier studies. This prospective study recruited 93 patients with SVT. The mean age of participants was  $47.88 \pm 15.66$  years with a female: male ratio of 1.73. The researchers found that the SVT rate was not affected by the patient's medical and drug histories.<sup>13</sup> Further, the rate of SVT was not affected by the patients' sociodemographics and blood pressures. Other earlier

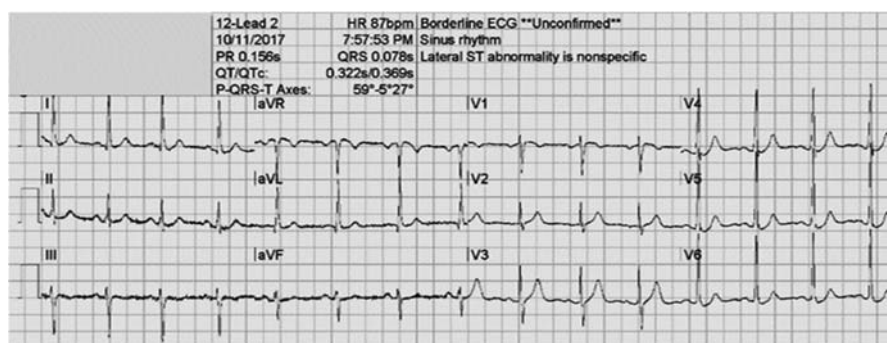


Figure 3. Electrocardiogram 2: Post-MVM pSVT conversion

studies achieved lower conversion rates of SVT using the MVM; Appelboam et al.,<sup>10</sup> achieved a 43% conversion rate, Walker and Cutting<sup>15</sup> achieved a conversion rate of 31.6%, and Corbacioglu<sup>23</sup> 42.9% in their RCT.

This study was limited as the patient experienced an isolated episode of pSVT and was stable at the two-month cardiology follow-up. Therefore, no other cardiology investigations were conducted, and the cause for this isolated episode of pSVT remains unknown. If the patient presents with recurring episodes of pSVT in the future, an echocardiogram, and a 48-hour Holter monitoring test would be ordered. If Wolff–Parkinson–White syndrome is diagnosed with delta waves presentation, then

ablation of the accessory pathway will be discussed with the patient.

## CONCLUSION

This case report is one example of the effectiveness of the MVM in terminating pSVT, without any escalation in treatment or adverse events. It is thus recommended that ambulance service agencies consider the inclusion of the MVM for the treatment of symptomatic pSVT, where traditional VM is already being used. The MVM could also prove particularly useful in countries with underdeveloped prehospital care services, or in remote areas with limited access to drugs. However, further prehospital studies in this area are warranted.

## REFERENCES

- Orejarena LA, Vidaillet H, DeStefano F, Nordstrom DL, Vierkant RA, Smith PN, et al. Paroxysmal supraventricular tachycardia in the general population. *J Am Coll Cardiol*. 1998;31(1):150–7.
- Page RL, Joglar JA, Caldwell MA, Calkins H, Conti JB, Deal BJ, et al. 2015 ACC/AHA/HRS guideline for the management of adult patients with supraventricular tachycardia. *J Am Coll Cardiol*. 2016;67(13):e27–e115.
- Al-Zaiti SS, Magdic KS. Paroxysmal supraventricular tachycardia: pathophysiology, diagnosis, and management. *Crit Care Nurs Clin*. 2016;28(3):309–16.
- Katritsis DG, Boriani G, Cosio FG, Hindricks G, Jais P, Josephson ME, et al. European Heart Rhythm Association (EHRA) consensus document on the management of supraventricular arrhythmias, endorsed by Heart Rhythm Society (HRS), Asia-Pacific Heart Rhythm Society (APHRS), and Sociedad Latinoamericana de Estimulación Cardíaca y Electro-fisiología (SOLAECE). *EP-Europace*. 2017;19(3):465–511.
- Colucci RA, Silver MJ, Shubrook J. Common types of supraventricular tachycardia: diagnosis and management. *Am Fam Physician*. 2010;82(8):942–52.
- Kamel H, Elkind MS, Bhave PD, Navi BB, Okin PM, Iadecola C, et al. Paroxysmal supraventricular tachycardia and the risk of ischemic stroke. *Stroke*. 2013;44(11):3111–16.
- Chen C, Tam TK, Sun S, Guo Y, Teng P, Jin D, et al. A multicenter randomized controlled trial of a modified Valsalva maneuver for cardioversion of supraventricular tachycardias. *Am J Emerg Med*. 2019;Epub August 1.
- Sohinki D, Obel OA. Current trends in supraventricular tachycardia management. *The Ochsner J*. 2014;14(4):586–95.
- HMCAS. Clinical practice guidelines. In: Hamad Medical Corporation Ambulance Services, editor. 2020 ed. Qatar: Hamad Medical Corporation Ambulance Service; 2020.
- Appelboam A, Reuben A, Mann C, Gagg J, Ewings P, Barton A, et al. Postural modification to the standard Valsalva manoeuvre for emergency treatment of supraventricular tachycardias (REVERT): a randomised controlled trial. *Lancet*. 2015;386(10005):1747–53.
- Smith G, Boyle MJ. The 10 mL syringe is useful in generating the recommended standard of 40 mmHg intrathoracic pressure for the Valsalva manoeuvre. *Emerg Med Australas*. 2009;21(6):449–54.
- Taylor DM, Wong LF. Incorrect instruction in the use of the Valsalva manoeuvre for paroxysmal supraventricular tachycardia is common. *Emerg Med Australas*. 2004;16(4):284–7.
- Mohammad AM, Saeed MS, Migliore F. Effectiveness of the modified Valsalva maneuver in the emergency management of supraventricular tachycardia. *Medical Journal of Babylon*. 2019;16(2):104–7.
- Tachycardia Narrow Complex Clinical Practice Guidelines. In: Queensland Ambulance Service, editor. Australia: Queensland Government; 2017.
- Walker S, Cutting P. Impact of a modified Valsalva manoeuvre in the termination of paroxysmal supraventricular tachycardia. *Emerg Med J*. 2010;27(4):287–91.

16. Smith GD, Fry MM, Taylor D, Morgans A, Cantwell K. Effectiveness of the valsalva manoeuvre for reversion of supraventricular tachycardia. The Cochrane Library. 2015; *Cochrane Database Syst Rev.* 2013;3.
17. Smith G. Management of supraventricular tachycardia using the Valsalva manoeuvre: a historical review and summary of published evidence. *Eur J Emerg Med.* 2012;19(6):346–52.
18. Appelboam A, Gagg J, Reuben A. Modified valsalva manoeuvre to treat recurrent supraventricular tachycardia: description of the technique and its successful use in a patient with a previous near fatal complication of DC cardioversion. *Brit Med J.* 2014;2014: bcr2013202699.
19. Rayburn D, Wagers B. Modified valsalva maneuver for pediatric supraventricular tachycardia. *Pediatr Emerg Care.* 2020;36(1):e8–e9.
20. Morley-Smith EJ, Gagg J, Appelboam A. Cardioversion of a supraventricular tachycardia (SVT) in a 7-year-old using a postural modification of the valsalva manoeuvre. *Case Reports.* 2017;2017: bcr2016218083.
21. Davis WD, Norris KC, Fiebig W. The modified valsalva maneuver for reversion of stable supraventricular tachycardia: lessons learned from the REVERT trial. *Adv Emerg Nurs J.* 2019;41(3):192–7.
22. Pandya A, Lang E. Valsalva maneuver for termination of supraventricular tachycardia. *Ann Emerg Med.* 2015;65(1):27–9.
23. Çorbacıoğlu ŞK, Akıncı E, Çevik Y, Aytar H, Öncül MV, Akkan S, et al. Comparing the success rates of standard and modified valsalva maneuvers to terminate PSVT: a randomized controlled trial. *Am J Emerg Med.* 2017;35(11):1662–5.